

VI. Problems with Nomenclature

Because anatomy deals with the description of structure, it is critically dependent on a precise, well-defined vocabulary. The vocabulary used to describe the structure of the body, including the brain, has been evolving over the course of more than 2,300 years, since the first great body of work on comparative anatomy by Aristotle. This evolution was rather haphazard until the 1880s, when several committees evaluated an astounding 50,000 anatomical terms, and over the course of 8 years pruned them down to about 4,500 (see Eycleshymer 1917; Staubesand and Steel 1988; O’Rahilly 1989). The result was the *Basle Nomina Anatomica* (BNA, His 1885), which was a systematic, hierarchically organized nomenclature tree that was widely adopted for most parts of the body, and has since undergone five official revisions.

However, the BNA not been used by neuroanatomists. Instead, neuroanatomical nomenclature has remained confusing, inconsistent, complex, and imprecise. Just as one example, more than 20 different lamination schemes for the primary visual area of the cerebral cortex have been proposed, and even reviews of this work generate controversy (Billings-Gagliardi et al., 1974; Valverde 1977).

There are many reasons for this state of affairs, all of which can be traced ultimately to the fact that the structure of the brain is vastly more complex and less understood than the other organ systems of the body. Thus, many parts of the brain have been identified, named, and delineated on the basis of considerably less than complete information, and as new methods are developed and more work is done, our understanding of its basic components has changed, and

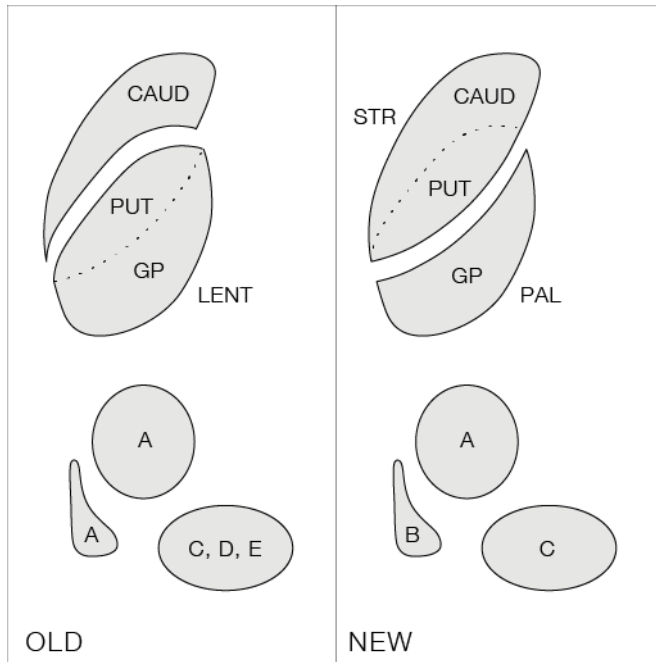


Fig. 9. Schematic view of how neuroanatomical nomenclature may change over time; see text for details. Abbreviations: A, B, C, D, and E, hypothetical names for indicated cell groups; CAUD, caudate nucleus; GP, globus pallidus; LENT, lenticular nucleus; PAL, pallidum; PUT, putamen; STR, striatum.

will continue to change. In fact, a very good argument can be made for the position that attempts to enforce a standardized nomenclature for the brain are counterproductive because they inhibit work designed to understand the true structure of the brain, and encourage the perpetuation of current misunderstandings. In short, it is essential that neuroanatomical nomenclature remain flexible. Having said this, it is important to emphasize that not all data and names are equally

valid.

Before describing how the nomenclature used here was selected, it is important to consider in more detail the nature of certain problems associated with the ultimate development of a standardized nomenclature for the nervous system (Fig. 9). Five types of problem come readily to mind. First, there is the problem of synonyms: virtually every structure in the brain has been referred to in a number of different ways at one time or another—and in many languages. In theory, the solution to this problem is trivial, but in practice the scholarship needed to establish thorough, accurate lists of synonyms, let alone more complex relationships, is a difficult exercise that has rarely been practiced. Second, the same name has been used for entirely different structures. Third, the boundaries of a particular structure are often placed differently by different

workers, or differently by the same worker in different papers; and similarly, the subdivision of a particular structure often varies.

An obvious consequence of changing the boundaries of one structure is that the boundaries of all neighboring structures must also change in a corresponding way. Another likely consequence is that the properties of regions enclosed by different borders are not identical. Fourth, two very different structures may be incorrectly grouped together under one name. A well-known example is the now obsolete “lenticular or lentiform nucleus”, a term introduced by Burdach (1819-26). This “nucleus” includes the globus pallidus and putamen, and it is now clear on architectonic and connectional grounds that the putamen and caudate nucleus form part of one structure, the striatum, whereas the globus pallidus is a major component of the pallidum (see section VIII, Tables A and B). The term “lenticular nucleus” does refer to a gross anatomical feature of the human brain, but it is rapidly and rightly going out of use. And fifth, new structures may be discovered, and this, of course, necessitates a redefinition of all neighboring structures as well.

From a very practical standpoint, it is easy to appreciate why these problems retard progress in neuroanatomy, and why they will actually become more serious as workers rely increasingly on key words in computer-assisted literature searches. However, they also raise two important questions: first, how are structures identified, and borders drawn in the brain; and second, how should names for structures be chosen?

The identification of structures—and for now we shall limit the discussion to discrete cell groups (regions)—is a process that has evolved greatly over the years, but at the present time most workers agree that a combination of architectonic and connectional criteria must be taken into account (section IVA). A cell group may be laminated or not (in which case it is usually referred to as a *nucleus*), and almost always contains more than one type of neuron, in addition to

glial and vascular cells. What defines a cell group, or one of its subdivisions, is a unique, identifiable distribution pattern of cell types.

The fundamental problem of neuroanatomy is to define what constitutes a cell type. Again, there is general agreement that neurons with the same pattern of axonal projections and the same set of inputs form a cell type (see Cajal 1995, Swanson 1996, 2003a), although it is possible that in the future certain combinations of biochemical features may need to be added; for example, the differential expression of neurotransmitters or receptors for neurotransmitters or hormones may serve to distinguish subsets of anatomically-defined cell types. For technical reasons, it is often very difficult to establish the existence and complete distribution pattern of a particular neuronal cell type.

The second question that needs to be dealt with is: how should names for structures be chosen? The overriding principle to bear in mind here is that neuroanatomical nomenclature is part of a language that is meant to convey spatial (and often functional) information; therefore, it seems obvious that nomenclature should be as simple, descriptive, unambiguous, and applicable across species as possible. With over a thousand named structures in the brain, it is little wonder that occasional, well-intentioned attempts to name regions of the brain in an “objective” way with numbers or letters have virtually always failed because they convey little or no positional, structural, or functional information, which is important for mnemonic purposes. Furthermore, the discovery of new structures often ruins the logic of the original numbering scheme.

In dealing with all of the problems associated with developing the most useful nomenclature, it might seem best just to apply the criteria of simplicity, descriptiveness, clarity, and generality mentioned above. However, there is a strong belief among taxonomists that historical precedence should also play a major role in determining what name is used. In practice, this criterion is also

frequently surrounded by controversy: should precedence be granted to the first illustration, the first mention in print, the first name, the first really adequate description, or the currently fashionable description?

The nomenclature adopted here was guided by the principles that the best names are simple, descriptive, unambiguous, and applicable across species, and that when several synonyms are in common use, that with historical precedence should be favored. However, the field is so complex and requires so many subjective judgments that no two professional neuroanatomists agree on all or even most aspects of nomenclature and parcellation. And it must be admitted that historical precedence alone is not necessarily a useful criterion; logic must ultimately prevail. The best example of this is the development of today's widely accepted nomenclature for the thalamus (Berman and Jones 1982): so many cell groups are involved that it is now parcelled successively into divisions, groups, nuclei, and subnuclei (and then cell types within subnuclei). The important point here is that consensus has emerged in naming many thalamic nuclei: word order is determined by the parcelling order just referred to. For example, the small-celled part of the posterior nucleus within the ventral group of the dorsal division is known as the *ventral posterolateral nucleus, parvicellular part*; a functional synonym (which is more convenient) is the *thalamic gustatory nucleus*. Wherever possible, we have tried to apply the above word order rule to the nomenclature adopted here, and to do so in American English. In addition, we have sometimes resorted to functional synonyms, particularly in the cerebral cortex, where they are rather widely used.

In closing this section, it may be useful to point out that brain structures may be described systematically in three ways, in terms of topography, systems, and neurochemistry. In topographical descriptions, which are the least informative, structures are merely related to the

major part of the brain in which they reside, be it forebrain, midbrain, hindbrain, and so on, and/or to their position in space (for example, the ventromedial nucleus of the hypothalamus). It would be convenient if a common set of terms for describing locations in the vertebrate nervous system were to evolve; in the meantime, a confusing array of synonyms and so on is in use (see Williams 1995; Swanson 2003a). The terms used wherever possible here are outlined in Figure 3.

The description of structures in relation to functional systems is another venerable approach that is particularly useful from a behavioral point of view, even if all of the systems are not known or understood. And finally, the description of structures or cell types strictly on histochemical grounds is quite recent, and has particular relevance to pharmacological applications, where a drug may act on a particular type of receptor, even if it is distributed in many cell types across different (superficially unrelated) functional systems. The first clear example of this approach was provided by Dahlström and Fuxe (1964), who classified neurons (with letters and numbers) on the basis of their content of biogenic amines, not their cytoarchitecture or connections.