III. Summary of Nervous System Development

The overview of mammalian nervous system development presented here is not based on tracings from histological sections. Instead, it is intended to show in a schematic, undoubtedly oversimplified way how the major subdivisions of the nervous system differentiate out of one primary germ layer, the ectoderm, that begins as an essentially flat, elliptical sheet of cells early in embryogenesis. What is the position of the major subdivisions within this sheet (FIG. 1), and how does this pattern change and differentiate as development progresses through the formation of a neural tube (FIGS. 2-5)? This is a classical problem in embryology, and involves the construction of what are referred to as *fate maps*, or maps that indicate the presumptive location of structures that can be identified at later stages of development.

One advantage of this approach is that basic design principles—perhaps even the "fundamental plan" (see Cajal 1909-1911; Kingsbury 1922; Herrick 1948; Bergquist and Källén 1954)—of the vertebrate nervous system may eventually emerge by considering the major components before they undergo their own, more or less elaborate, pattern of differentiation. This may in turn yield more effective ways to represent the components of the adult nervous system graphically, especially in two-dimensional maps (FIGS. 6-10).

It is not our intention here to review what is known about cellular and molecular mechanisms underlying nervous system differentiation; there are a number of excellent introductions to this fundamental problem (see, for example, Balinsky and Fabian 1981; Purves and Lichtman 1985). Nor shall we review in detail attempts to refine experimentally the organization of vertebrate nervous system fate maps, most of which have been carried out in nonmammalian embryos. However, a useful introduction to the problem, which includes a fate map for the 32-cell stage of the *Xenopus* embryo, maybe found in Dale and Slack (1987), and the most relevant literature will

be mentioned in the text accompanying the Figures. It is important to appreciate, however, that early stages of nervous system development are thought to be fundamentally similar in all vertebrates.

FIG. 1 is a dorsal view of the *trilaminar embryonic or germ disc*. For those not familiar with the earlier stages of embryogenesis, it may be useful to point out that this structure is preceded by an even simpler *bilaminar embryonic or germ disc*, which contains two layers of cells (*primary embryonic or germ layers*), the *embryonic ectoderm* (epiblast), and the *embryonic endoderm* (hypoblast), which in turn are derived from a relatively undifferentiated *inner cell mass*. Good introductions to these stages of development may be found in Hamilton and Mossman (1972), Sadler (1985), and Williams et al. (1989), and the bilaminar stage is illustrated schematically in text fig. 9, where it can be seen that the *amnionic cavity* is formed by a layer of cells that appears to be continuous with the embryonic ectoderm, whereas the *secondary yolk sac cavity* is formed by a layer of cells that appears to be continuous with the embryonic endoderm.

The bilaminar disc is transformed during the process of *gastrulation* into a trilaminar disc by the formation of a third primary cell layer, the *mesoderm*; these cells arise from a differentiated median region of caudal embryonic ectoderm—the *primitive streak*, and its rostral pole, the *primitive (Hensen's) node*—and then migrate between the embryonic ectoderm and embryonic endoderm to form an intermediate layer. Mesodermal cells derived from the primitive node tend to migrate rostrally along the midline (see Selleck and Stern 1991), where they form a rod-like condensation of cells referred to as the *notochordal or head process*, which later gives rise to the definitive *notochord*. This midline invagination of cells derived from the primitive node is of primary importance because the early notochordal process releases a diffusible substance (or substances) that *induces* differentiation in overlying (or adjacent) midline regions of the

ectoderm. This differentiation generates the *neural plate*, which eventually gives rise to the *central nervous system*, the first organ system to begin differentiation in the embryo.

It may be worth pointing out that the *oropharyngeal membrane* forms a barrier to the rostral migration of mesodermal cells forming the notochordal process. This "membrane" consists of a thickened disc of embryonic endoderm, along with closely opposed regions of the embryonic ectoderm—with no intervening mesoderm. It appears to be the first differentiation of the bilaminar disc, and along with the primitive streak and node (which together constitute the second differentiation) it serves to define the rostrocaudal axis of bilateral symmetry in the embryo.

Finally, it should be noted that the early embryonic disc in rodents is not relatively flat, but is instead cup-shaped (U-shaped in longitudinal sections), a condition that is sometimes referred to (in an unnecessarily obscure way) as *inversion or entypy of the germ layers*. It is important to bear in mind, however, that there is nothing unusual about the topology of the rodent embryonic disc (see fig. 3 in Meier and Tam 1982; as well as Huber 1915; Matsuda 1991). The histology of the developing albino rat—from fertilization through the first indications of mesoderm formation late on the eighth day after insemination (embryonic day 8, e8)—has been described elegantly by Huber (1915; also see Hebel and Stromberg 1986). Similarly detailed descriptions of subsequent neurulation (neural tube formation) and *somite formation* in albino rat embryos have been provided by Adelmann (1925) and Butcher (1929), respectively.

Developmental Figures (10)

[Each figure is accompanied by a legend; the original format was oversized (leaf 44.1x28.7 cm), except for FIGURE 7, which was a double foldout (132.3x28.7 cm).]

FIGURE 1. A dorsal view of the *trilaminar embryonic disc* to show differentiation of the ectodermal layer into somatic and neural components (to the left of the midline), as well as a fate map of the presumptive location of various parts of the nervous system (to the right of the midline). In the rat, this stage of development occurs before the first pair of somites can be recognized, during the first half of embryonic day nine (Schwind 1928).

At this stage, the entire ectoderm is one cell layer thick, although *neuroectodermal* cells are taller and thus form a recognizable *neural plate*, which lies between Hensen's node (Hn) and the oropharyngeal membrane (opm), and may be divided somewhat arbitrarily into a rostral, much broader, *brain plate*, and a caudal, narrower, *spinal plate*. Thus, the neural plate as a whole gives rise to the two fundamental divisions of the *central nervous system*, the brain and spinal cord.

It now seems clear that the neural plate differentiates progressively from rostral to caudal (see Meier and Tam 1982; Nieuwkoop 1989), so that the brain plate can be recognized before the spinal plate. It follows from this that rostral parts of the brain plate may differentiate before caudal parts of the brain plate, and this feature is of fundamental importance when we come to discuss transverse segmentation of the neural tube in FIG. 3. However, it should be pointed out here that the first indications of this segmentation (after the distinction between brain and spinal plates) has long been thought to be the formation of *three primary vesicles* or swellings in the rostral half of the neural tube (von Baer 1828). From rostral to caudal, these are the *forebrain*, *midbrain*, and *hindbrain* vesicles, and from what has been said above, it could be anticipated that the forebrain vesicle may be the first part of the nervous system to show signs of differentiation (Nieuwkoop 1989). The presumptive location of these vesicles is indicated in FIG. 1, along with the presumptive location of the major subdivisions of the forebrain vesicle (the diencephalon and telencephalon) and hindbrain vesicle (the medulla and pons) that serve to define the five-vesicle stage of development (FIG. 4).

Thus, the neural plate generates a series of bulges or *neuromeres* that are arranged from rostral to caudal and help to define the basic subdivisions of the central nervous system. In addition, the neural plate and adjacent regions may be divided into a series of *longitudinal strips* that run the length of the neural plate, from the oropharyngeal membrane to Hensen's node. At the stage of development shown here, it has been reported that the neural plate consists of a single median strip of cells, and two lateral strips of cells, one on either side (Alvarez and Schoenwolf 1991). It is not known whether the median and lateral strips are related to the *basal and alar plates* that develop later (in the neural tube stage) and are separated by the *sulcus limitans*. In any event, as discussed in FIG. 4, it is often stated that the basal and alar plates divide the central nervous system into longitudinal motor (medial in the neural plate and then ventral in the neural tube) and sensory (lateral and then dorsal) zones.

Most of the *peripheral nervous system* develops from another longitudinal strip between the lateral edge of the neural plate and the somatic ectoderm: the *neural crest*, which may first be identified just before the stage illustrated in FIG. 2 (Adelmann 1925). In addition to certain non-neural tissues, the neural crest appears to give rise to the *spinal sensory ganglia*, the *autonomic ganglia* (including the *enteric nervous system*), and at least part of the sensory ganglia associated with the cranial nerves (see Adelmann 1925; Bartelmez 1962; Altman and Bayer 1984; Tan and Morriss-Kay 1986; Hall 1988; LeDouarin and Smith 1988).

The remainder of the peripheral nervous system arises from a series of bilateral *placodes*, which are localized regions of thick ectoderm. The o*lfactory placodes* (olp), which give rise to *olfactory sensory neurons* and the *terminal ganglia* (GTE), differentiate opposite the presumptive telencephalon in a continuation of the neural crest region that surrounds the rostral end of the brain plate and is now commonly referred to as the *anterolateral ridge* (alr; see Couly and LeDouarin 1985, 1990). In the mouse, olfactory placodes become recognizable at around the 20

somite stage of development, illustrated here for the rat in FIG. 3 (see Verwoerd and van Oostrom 1979). The presumptive *hypophysial placode* (hp), which gives rise to the anterior and intermediate lobes of the pituitary gland, is an unpaired median region in the anterolateral ridge, between the oropharyngeal membrane and the front of the brain plate (the hypothalamus, HY; see Couly and LeDouarin 1985); in the rat, the placode itself may be recognized at about the 20 somite stage, on embryonic day 11 (see Schwind 1928; Simmons et al. 1990).

Finally, there is a series of *placodes* lateral to the neural crest at the level of the hindbrain that gives rise to some or all (the proportion is not known with certainty) of the sensory ganglion cells associated with the trigeminal (V), facial (VII), vestibulocochlear (VIII), and glossopharyngeal (IX) and vagus (X) cranial nerves (see Adelmann 1925; Verwoerd and van Oostrom 1979; LeDouarin and Smith 1988). In the rat, it would appear that five placodes may be involved: the *trigeminal placode* (forming the semilunar ganglion), the *facial placode* (forming the geniculate ganglion), the *otic placode* (forming the vestibular and then the cochlear or spiral ganglia), and two placodes associated with the glossopharyngeal and vagus nerves, the *distal glossopharyngeaovagal placode* (forming the petrosal and nodose ganglia, which relay special visceral sensory information through the glossopharyngeal and vagus nerves, respectively), and the *proximal glossopharyngeaovagal placode* (forming the superior petrosal and jugular ganglia, which relay somatic sensory information through the glossopharyngeal and vagus nerves, respectively); all of these placodes may first be distinguished histologically between embryonic days 11 and 12 (see Altman and Bayer 1982).

Thus, the presumptive locations of the major divisions of the nervous system are rather clearly displayed at the neural plate stage, when they are arranged in a relatively flat sheet of cells.

Abbreviations.

alr	anterolateral ridge
AMN	amnion (cut edge)
BG	basal ganglia
cr	cardiogenic region
CTX	cerebral cortex
GTE	terminal ganglion
Hn	Hensen's node
hp	hypophysial placode
HY	hypothalamus
IX/Xpd	distal glossopharyngeal/vagal placode
IX/Xpp	proximal glossopharyngeal/vagal placode
lep	lens placode
olp	olfactory placode
opm	oropharyngeal membrane
otp	otic placode
prs	primitive streak
TH	thalamus
VIIIp	otic placode
VIIp	facial placode
Vpla	trigeminal placode

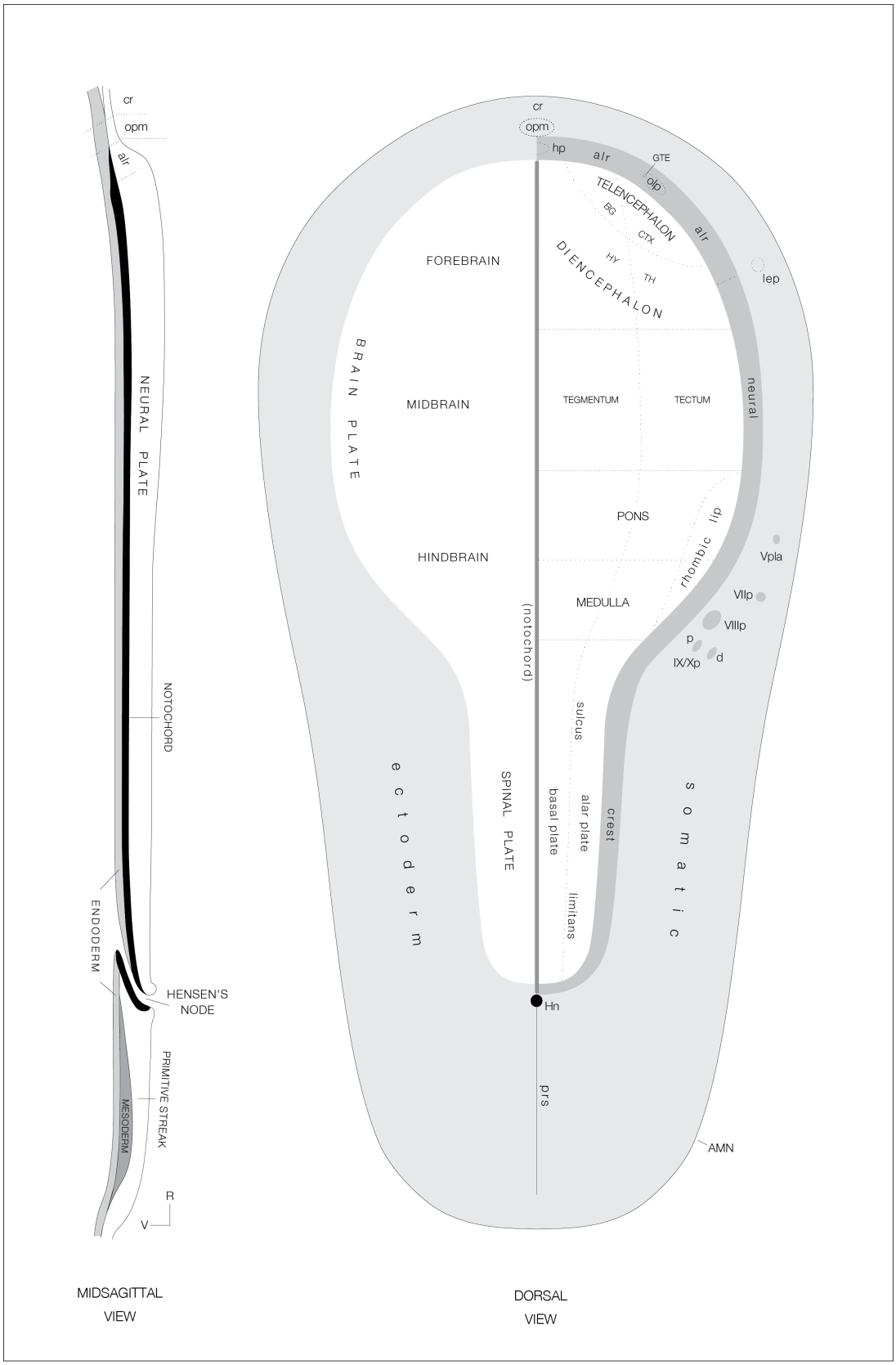

FIG. 1 *The Neural Plate (Presomite)*

FIGURE 2. This figure illustrates the well-known sequence of events leading from the neural plate to a fluid-filled *neural tube* that separates from the somatic ectoderm and comes to lie within dorsal parts of the embryo, between the notochord and dorsal midline regions of the somatic ectoderm. The *neuroectoderm* at this stage is still a pseudostratified proliferative epithelium in which no definitive cell types (neurons or glial cells) have differentiated.

In mammals, the lateral edges of the neural plate, which are, of course, thrown into *neural folds* at this point, tend first to meet and then fuse in the transitional region between the brain and spinal plates, in cervical regions of the embryo where the first *somites* (1-7) also differentiate out of paraxial mesoderm. In the rat, specifically, the first several pairs of somites appear during the second half of embryonic day 9, and by the middle of the tenth day about ten have become recognizable; furthermore, it seems likely that they differentiate from rostral to caudal at the rate of about one pair every two hours (Schwind 1928; Butcher 1929; Christie 1964). Many important changes take place during the relatively short time when the first 50 or so pairs of somites form, so that their actual number provides the most convenient and accurate means for describing embryonic age during this period. For example, the neural tube in the rat begins to form in mid-rostrocaudal levels of the neural plate at about the 6-7 somite stage (Christie 1964), and the dorsal fusion then proceeds in the rostral as well as the caudal direction; it is completed with closure of the rostral neuropore at about the 15-18 somite stage (Schwind 1928; Bartelmez 1962; Christie 1964) and closure of the caudal neuropore at about the 23-25 somite stage (see Christie 1964). Mechanical factors related in part to rapid lengthening of the neural plate may participate in the initial closure of the neural tube (Jacobson and Tam 1982; Jacobson 1984). It should also be mentioned that recent evidence suggests that mesenchyme in the head region of the early embryo forms poorly differentiated somites, or *somitomeres*, which are related in a clear way to the three

primary divisions of the brain plate, before the formation of definitive somites in the cervical region (see Meier and Tam 1982; Keynes and Lumsden 1990).

The region to the left of midline in the dorsal view illustrates major features that have been described in the neural tube at this stage, whereas the presumptive location of certain other features that will appear later are shown to the right of midline. Segmentation of the neural tube, and the formation of three primary brain vesicles was alluded to in FIG. 1. However, it should be emphasized here that there is disagreement about the details of all aspects of this segmentation (for recent reviews, see Vaage 1969; Keyser 1972). On the other hand, earlier concerns that various bulges seen in the neural tube may be artifactual appear to have been dispelled; suggestions that at least some of the swellings (or *neuromeres*) may represent isolated proliferative compartments (see Orr 1887; Källén 1953; 1962) has received strong experimental support recently (for review, see Guthrie and Lumsden 1991). However, there is still disagreement about when and where many of the swellings appear, undoubtedly reflecting a very complex spatiotemporal pattern of expression.

Bearing these caveats in mind, it appears likely that at about the 5 somite stage in the rat, two bulges appear within the walls of the neural plate, a rostral *optic vesicle* (ovp) or neuromere, and a caudal otic neuromere (not illustrated here); and that very shortly thereafter (around 7-9 somites) *boundaries separating the midbrain from the forebrain* and *then the midbrain from the hindbrain* become clear (Adelman 1925; 1936 a,b; Bartelmez 1962). The fate of the optic vesicle is obvious: it rapidly evaginates to form the neural retina, whereas the otic swelling appears to divide the hindbrain vesicle into three parts (neuromeres, or more specifically, rhombomeres) at this stage.

Two other features are of particular interest during this period of development. First, a differentiation of the midline neuroectoderm, the *floor plate*, may be identified in the region of the hindbrain vesicle and spinal cord of many species, and it has been claimed that the floor plate

comes to an end at the midbrain-hindbrain junction in all vertebrates (Kingsbury 1934). Since no clear boundary between the hindbrain and spinal cord has ever been identified, it has thus been suggested from time to time over the years that the two fundamental subdivisions of the central nervous system are in fact the spinal cord and hindbrain on the one hand, and the midbrain and forebrain (together forming the *cerebrum*) on the other (see von Kupffer 1906; Keyser 1972).

The second particularly interesting feature at this stage is the relatively massive expansion of the forebrain, a significant proportion of which appears to occur by way of a rostral flow of cells from more caudal regions (Morriss-Kay 1981; Morriss-Kay and Tuckett 1987). Combined with evidence mentioned in FIG. 1 that the forebrain is the first part of the neural plate to differentiate, it would appear that it contains cells generated endogenously, as well as cells entering from more caudal regions. The extent to which these cells are intermixed (particularly very rostrally, for example in the presumptive telencephalic region) is not known. Despite this, however, the fate map illustrated on the right side of the midline appears to receive support from experimental work in the amphibian neural plate (see Jacobson 1959; Eagleson and Harris 1990).

Abbreviations.

BG basal ganglia

CTX cerebral cortex

FB forebrain

fpl floor plate

HB hindbrain

HY hypothalamus

lam lamina terminalis

MB midbrain

nch	notochord
NCR	neural crest
ng	neural groove
NPL	neural plate
NT	neural tube
ovp	optic vesicle primordium
SE	somatic ectoderm
sl	sulcus limitans
SPP	spinal plate
TC	tectum
TG	tegmentum
TH	thalamus

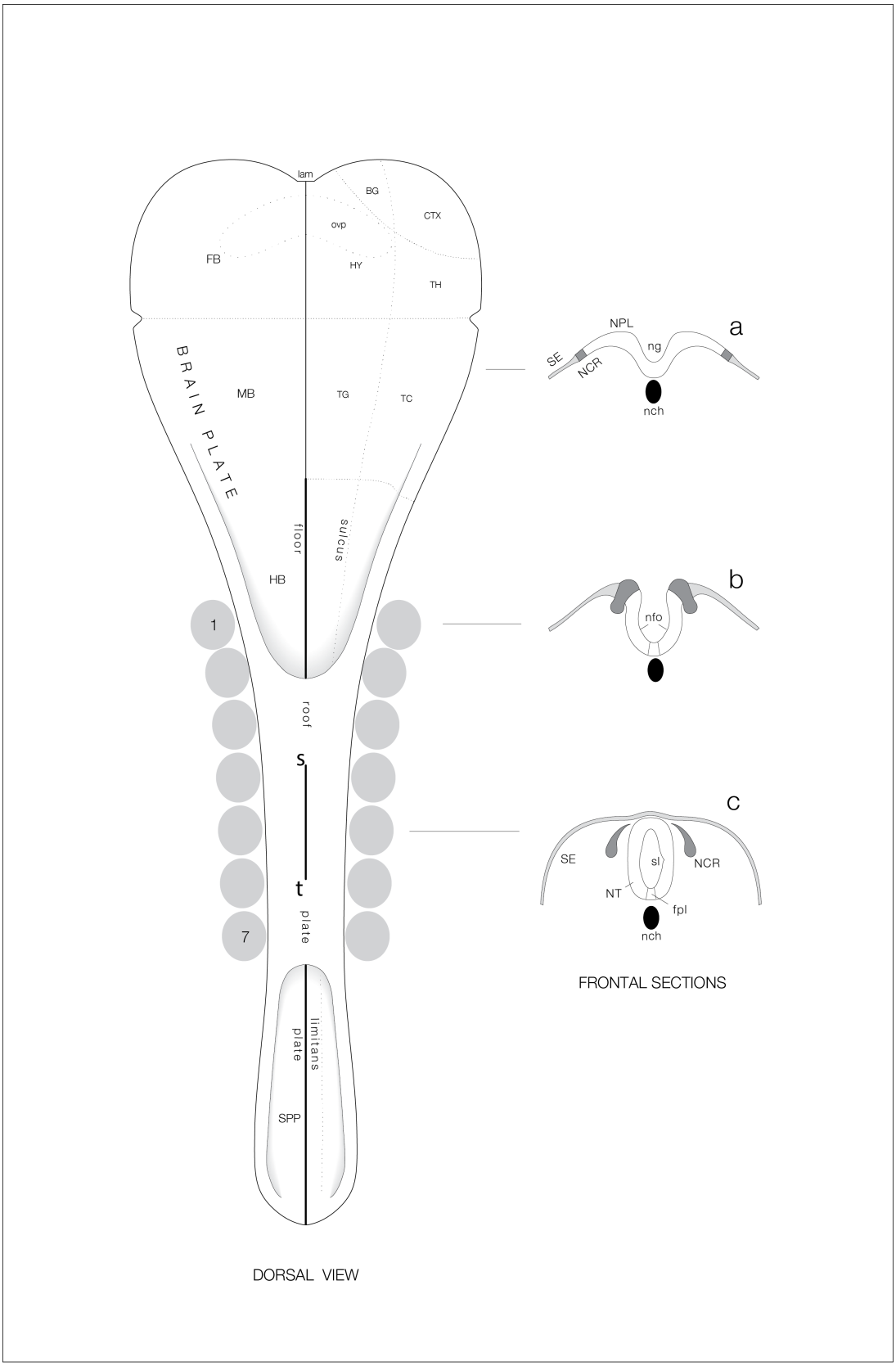

FIG. 2 *Neural Tube Closure (7 Somites)*

FIGURE 3. The drawing on the left illustrates the appearance of the neural tube shortly after the rostral and caudal neuropores have closed (during the first half of embryonic day 11 in the rat). It is widely believed that three major swellings can be identified in the rostral half of the neural tube at this stage, corresponding to the forebrain, midbrain, and hindbrain vesicles. Note that the neural tube as a whole has adopted a C-shape. The dorsal bending (the *cephalic or midbrain flexure*; cf) is more acute, and is associated with the head fold. Also note that the optic vesicle has evaginated and left behind nothing more than an optic stalk in the ventral wall of the forebrain vesicle, and that the hindbrain vesicle is more differentiated than at the stage shown in FIG. 2. As we shall see (FIG. 4), it is believed that the three primary brain vesicles or neuromeres subdivide into, or are replaced by (Bergquist and Källén 1954), a more complex set of secondary vesicles and/or neuromeres.

The drawing on the right shows a schematic extended or uncurved neural tube at the three vesicle stage, along with the presumptive location of major features that will emerge somewhat later (FIG. 4). Note especially that midline regions of the neural plate (FIGS. 1 and 2), which lie adjacent to the notochord, correspond to ventral parts of the neural tube, whereas the lateral edges of the neural plate fuse and come to lie in the dorsal midline of the neural tube. A definitive *floor plate* is said to be restricted to the ventral midline of the hindbrain vesicle and the spinal cord (Kingsbury 1934). On the other hand, the dorsal midline of the spinal cord and an indeterminate extent of the brain is formed by the *roof plate*, and the region between the rostral ends of the floor and roof plates are formed by what might be thought of as a "*terminal plate*"—part of which is associated with the familiar lamina terminalis. We are unaware of a name for the ventral midline region between the rostral end of the floor plate and the infundibulum. It is important to note that the first neurons to differentiate out of the neuroepithelium are found in ventral parts of the neural tube at this stage of development. It seems likely that all of these neurons are motor in function;

in the brainstem and spinal cord they are probably somatomotor, whereas in the forebrain they are probably neuroendocrine (for reviews, see Altman and Bayer 1986; Swanson 1992).

Abbreviations.

BG basal ganglia

cf cephalic flexure

CTX cerebral cortex

FB forebrain

fpl floor plate

HB hindbrain

hrp hindbrain roof plate

HY hypothalamus

MB midbrain

rnp rostral neuropore

sl sulcus limitans

sopt optic sulcus

SP spinal cord

TC tectum

TG tegmentum

TH thalamus

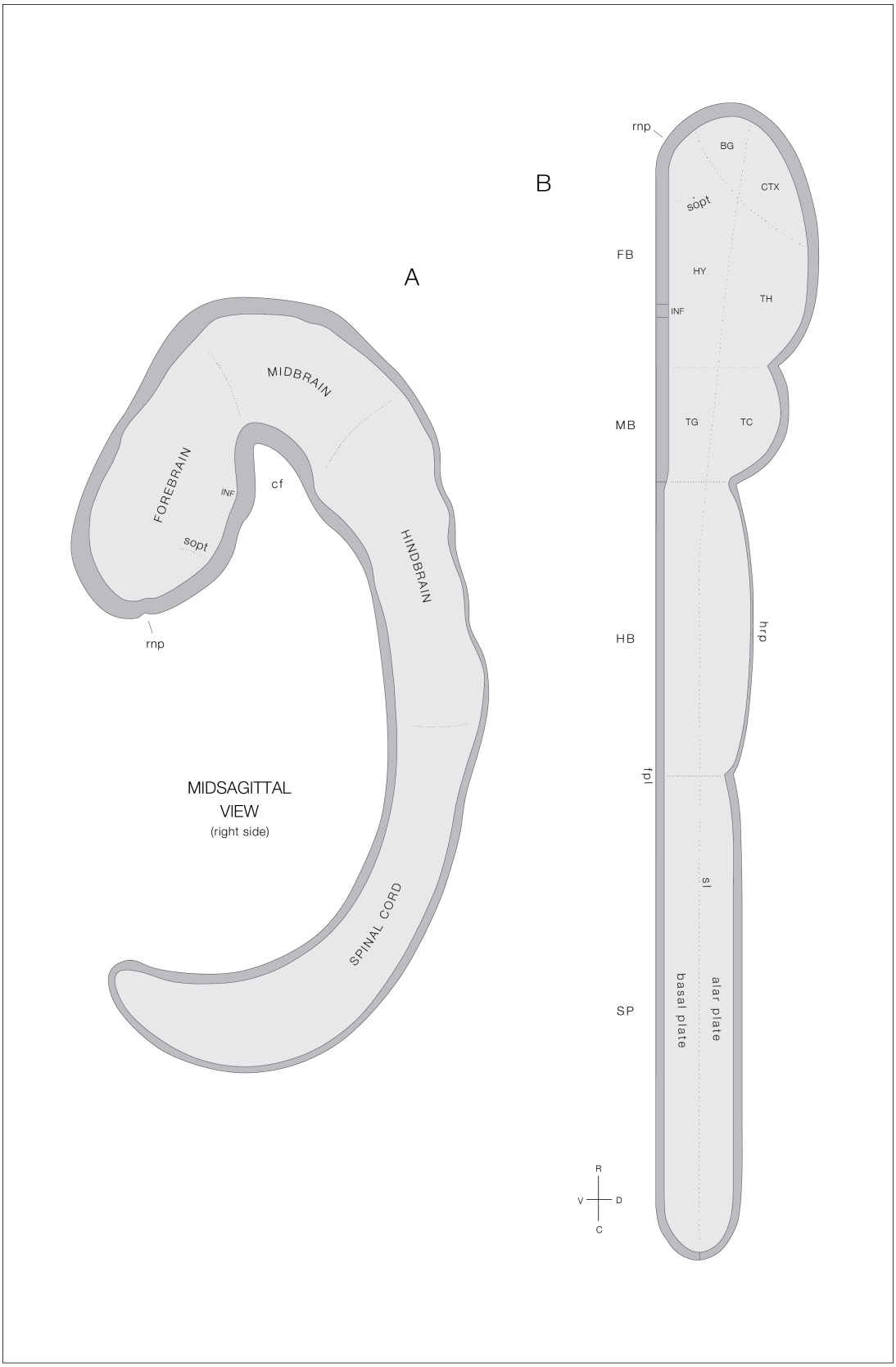

FIG. 3 *3 Vesicle Stage (20 Somites)*

FIGURE 4. **Part A** shows the major features apparent in the brain region of the neural tube at a time just after the *telencephalic vesicle* (TL) may be clearly distinguished from the *diencephalic vesicle* (DI) by a ridge called the *torus hemisphericus*. In addition, the *pons* (P) and *medulla* (MY) may now be distinguished in the region of the hindbrain vesicle. This is the classical five-vesicle stage of development: telencephalon and diencephalon, midbrain, and pons and medulla; it may be recognized in the rat during the first half of embryonic day 12. This stage is particularly important for descriptive purposes because it is the last time that the central nervous system may still be viewed conveniently as an essentially flat sheet, a condition that is made increasingly difficult by the rapid evagination of the telencephalic vesicles from rostrodorsal parts of the forebrain vesicle (FIG. 5). This stage has been particularly well-illustrated by Wilhelm His (1904) in his 6.9 mm human embryo, Br. 3, which was discussed further by Bailey (see fig. 15 in Bailey 1916), and used as the basis for this figure.

A series of longitudinal grooves also appears within the walls of the neural tube around this period of development. There seems to be little doubt that the *sulcus limitans* (sl, in Part B) divides the hindbrain and spinal cord into *alar* (dorsal) and *basal* (ventral) plates (His 1888), while there remains great confusion about its identity or even existence rostral to the hindbrain. This problem is of interest only because His attached functional significance to the longitudinal zones above and below the sulcus limitans, the basal plate being primarily motor and the alar plate being primarily sensory. It does seem likely that at early stages of development the basal plate contains primarily motor structures, but it has proven very difficult to define purely "sensory" structures, and it now seems more reasonable to think broadly of three longitudinal zones, *motor* (ventral), *associational* (intermediate), and *sensory relay* (dorsal) (see Herrick 1948; Altman and Bayer 1984; Tan and LeDouarin 1991).

In addition to the sulcus limitans, it appears firmly established that the hindbrain vesicle displays other longitudinal grooves that further divide both the alar and the basal plates into *somatic and visceral components* (with the latter lying closest to the sulcus limitans), and that the dorsal edge of the alar plate differentiates into a *rhombic lip* (RHL in Part B; for reviews, see Herrick 1913; Bergquist and Källén 1954; Harkmark 1954; Altman and Bayer 1984). Thus, the hindbrain appears to be divided into relatively clear longitudinal zones, as well as a series of transversely oriented neuromeres, which, it has been suggested, together form a matrix of relatively independent *proliferation/migration zones*, here and throughout the rest of the neural tube (see Bergquist and Källén 1954; Tuckett and Morriss-Kay 1985). There seems to be reasonable agreement that three primary neuromeres or rhombomeres may be first identified within the mammalian hindbrain, and that subsequently the number increases to six (Källén and Lindskog 1953; Bergquist and Källén 1954) or seven (Adelmann 1925; Bartelmez and Evans 1925).

As far as the *midbrain vesicle* (MB) is concerned, there seems to be agreement that early on it is divided (at least dorsally) into two large neuromeres (*mesomeres*) that correspond approximately to the superior and inferior colliculi (Adelmann 1925; Bartelmez and Evans 1925; Bergquist and Källén 1954). It should also be pointed out, however, that a neuromere between the diencephalon and midbrain—referred to as the *synencephalon* (SY) and correspondingly approximately to the pretectal region—has been identified (see Keyser 1972), and that the constricted region between the midbrain and hindbrain vesicles was often referred to as the *isthmus* (IS) in the older literature (see Gillilan 1943), although its exact components were never clearly defined, and it is now generally regarded as a rostral part of the pons. Finally, it seems generally agreed that the *sulcus limitans* extends into the midbrain vesicle, separating it in a broad

way into a dorsal tectum and a ventral tegmentum, although it is difficult to find convincing evidence for this in the literature.

A series of grooves also appear to converge on a site (fos in FIG. 4A) near the center of the *forebrain vesicle* at this stage. In essence, these grooves serve to divide the diencephalic vesicle into dorsal and ventral components (the *thalamus* and *hypothalamus*, respectively), and the telencephalic vesicle into dorsal and ventral components (the pallium or *cortex* and the *ventricular*—or *striatal—ridge*, respectively). The diencephalic groove is the *hypothalamic sulcus* (shy in Part B), whereas the telencephalic groove is the *lateral striatal sulcus* (ssl in Part B); their relationship to the *sulcus limitans* is entirely unclear.

Part B shows the presumptive location of certain features that will appear at shortly later stages of development. The major presumptive feature of the hindbrain vesicle is the rhombic lip (His 1890), a region with an extremely high proliferative capacity: it would appear that the rostral half or so gives rise to most of the cerebellar cortex, whereas progressively more caudal regions give rise to the vestibular and cochlear nuclei, the precerebellar nuclei (pontine gray, inferior olive, and lateral reticular nucleus), and the dorsal column nuclei (see Harkmark 1954; Taber Pierce 1966, 1967; Bourrat and Sotelo 1990). Topologically, it would appear to lie dorsal to the zone of the alar plate that gives rise to the sensory nuclei associated with the trigeminal, glossopharyngeal, and vagus nerves.

Three presumptive features of the forebrain vesicle deserve special comment. First, the thin *roof plate of the forebrain vesicle* lies in a strategic position, and an understanding of its disposition is essential for understanding the organization of this part of the brain; fortunately, Hines (1922) has provided a brilliant analysis of this problem. In essence, this roof plate has the shape of a Christian cross when viewed from above; the body of the cross lies in the midline, with

the longer part forming the *diencephalic roof plate* (drp), and the shorter part forming the *telencephalic roof plate* (trp); in contrast, the transverse arms extend laterally and ventrally along the torus transversus (in the *di-telencephalic groove* of Johnston 1909 that later forms the velum transversum), between the telencephalic vesicle and the thalamic part of the diencephalic vesicle. Strands of choroid plexus will later develop in the diencephalic and two *di-telencephalic roof plates* (dtrp). The rostral edge of the velum transversum is sometimes called the *sulcus ventralis* (hippocampus), while the caudal edge is sometimes referred to as the *sulcus terminalis*.

The second feature to note in the forebrain of Part B is the presumptive location of the *hippocampal formation* (php) in the presumptive cortical region: it forms a C-shaped limb or arch around the entire medial edge of the developing cerebral cortical mantle. And the third feature to note is the future development of *medial and lateral ventricular ridges* (VRl,m) in the region of the primary ventricular ridge. The possible significance of these telencephalic features will be considered further in FIG. 5.

Part C is a hypothetical unfolded view of the rostral half of the neural tube at the five-vesicle stage of development. It is designed to show primarily the (often presumptive) location of features that differentiate in or near the floor plate, the roof plate, and the region that connects them rostrally (the "terminal plate"). These structures constitute extremely useful landmarks during subsequent development. This map was constructed largely from information discussed in Warren (1917), Hines (1922), Schwind (1928), and Kingsbury (1934).

Abbreviations.

ac anterior commissure

AP area postrema

BG	basal ganglia
cc	corpus callosum
ccg	corpus callosum, genu
ccr	corpus callosum, rostrum
ccs	corpus callosum, splenium
cf	cephalic flexure
CMVE	caudal medullary vellum
CTX	cerebral cortex
dhc	dorsal hippocampal commissure
DI	diencephalon
drp	diencephalic roof plate
dtrp	di-telencephalic roof plate
fpl	floor plate
fr	fasciculus retroflexus
hbc	habenular commissure
hrp	hindbrain roof plate
HY	hypothalamus
IC	inferior colliculus
INF	infundibulum
IS	isthmus
IVd	decussation of the trochlear nerve
lam	lamina terminalis
MB	midbrain
ME	median eminence

MY	medulla
och	optic chiasm
OV	vascular organ of the lamina terminalis
P	pons
pc	posterior commissure
php	hippocampal primordium
PIN	pineal gland
PRT	pretectal region
RCH	retrochiasmatic area
RHL	rhombic lip
RMVE	rostral medullary velum
SC	superior colliculus
SCO	subcommissural organ
SFO	subfornical organ
shy	hypothalamic sulcus
sin	infundibular sulcus
sis	intrastriatal sulcus
sl	sulcus limitans
sme	sulcus medullaris
sopt	optic sulcus
SP	spinal cord
ssl	lateral striatal sulcus
ssm	medial striatal sulcus
ste	sulcus terminalis

sve	sulcus ventralis
SY	synencephalon
TC	tectum
TG	tegmentum
TH	thalamus
TL	telencephalon
trp	telencephalic roof plate
ttr	torus transversus
V3ir	third ventricle, infundibular recess
vhc	ventral hippocampal commissure
VRl	lateral ventricular ridge
VRm	medial ventricular ridge
vtr	velum transversum

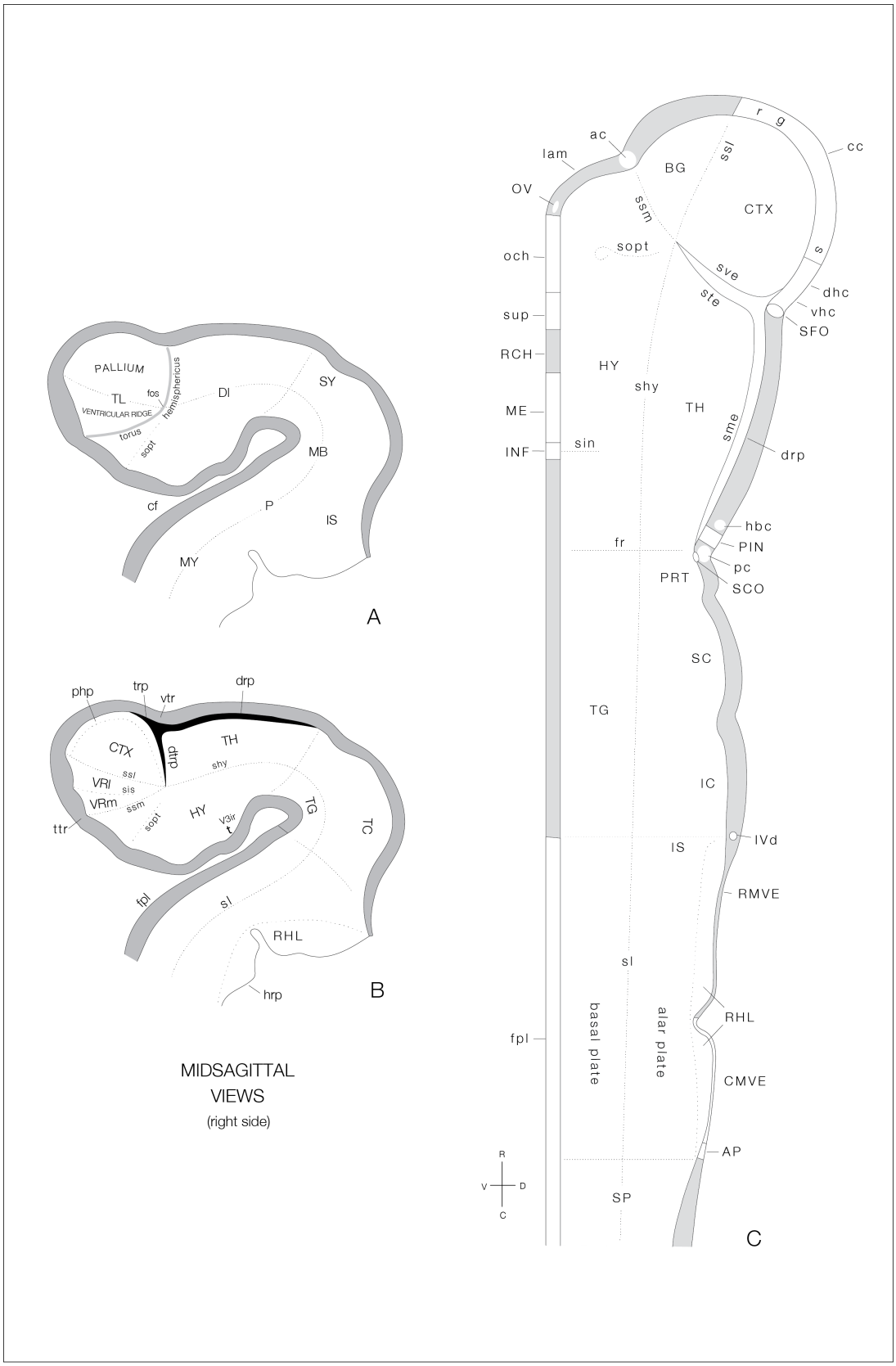

FIG. 4 *5 Vesicle Stage (30 Somites)*

FIGURE 5. This figure shows the initial stages of cerebral hemisphere evagination, along with further differentiation of regions within the wall of the forebrain vesicle. **Part A** is taken from FIG. 4C, and shows the approximate location of additional features that will develop shortly in each of its four major subdivisions: the thalamus, hypothalamus, basal ganglia, and cerebral cortex (pallium).

A majority of workers hold that a series of more or less longitudinal grooves divide the presumptive *thalamus* into three regions, the *epithalamus* (EPI), *dorsal thalamus* (DOR), and *ventral thalamus* (VNT). As defined here (see Section V.A), the dorsal thalamus contains all of the cortically projecting cell groups of the thalamus as a whole, and it is rather easy to indicate (Part A) the approximate location of the major groups of specific thalamic nuclei within the dorsal thalamus. Important issues of thalamic development have been reviewed thoroughly by Keyser (1972).

The adult *hypothalamus* may be divided into three longitudinal zones: periventricular (neuroendocrine motor), medial, and lateral (LZ); as well as four rostrocaudal levels (defined by major nuclei in the medial zone): preoptic (PRO), anterior (ANT), tuberal (TUB), and mammillary (MAM). At least in a general way, these levels may be defined by two embryonic grooves, the optic (sopt) and infundibular (sin) sulci (FIGS. 4C and 5A). One of the most contentious issues in forebrain development has centered on the rostral boundary of the hypothalamus: what belongs to the telencephalon and what belongs to the diencephalon? Since the time that His (1892, 1893) assigned the preoptic, anterior, and tuberal levels to the telencephalon, the border has moved progressively rostral, to the level shown here. Fundamentally, the contemporary rationale is that structures derived from the neuroepithelium of the lateral ventricle are telencephalic, whereas structures derived from the third ventricular neuroepithelium are diencephalic (see Bayer 1987; Bayer and Altman 1987; Ju and Swanson

1989). An introduction to some of the problems associated with hypothalamic development may be found in Keyser (1972, 1979) and Altman and Bayer (1986).

The further development of the *cerebral cortex* or pallium is associated primarily with establishing the various fields that receive inputs from the dorsal thalamus. Several general features of this differentiation are of particular interest here. First, it is clear that the region in the forebrain vesicle where so many of the grooves converge early on (FIG. 4A, fos) corresponds later to the *temporal pole* (TEP) of the cerebral hemisphere (FIG. 5A, B). Second, the temporal third of the hippocampal primordium undergoes tremendous proliferation, whereas the remainder forms the paltry induseum griseum of the adult, which stretches as far as the rostral tip of the prefrontal region (PFR in FIG. 5A; see Bailey 1915; Hines 1922). Third, on what seem to be straightforward topological grounds, it is easy to assign the presumptive location of the other major cortical regions (cingulate, frontal, parietal, occipital, insular, and rhinal) to the remainder of the cortical mantle (see Swanson 1983). And fourth, note that the *amygdala* (AMY) appears to develop partly from the cerebral cortex (mainly parts of the olfactory cortex referred to as the cortical and medial nuclei) and partly from the basal ganglia (the deep nuclei). We shall return to this point shortly. For more information on the development of the cerebral cortex in the rat (where neurons begin to differentiate around embryonic day 14), see Berry (1974) and Bayer and Altman (1991).

To earlier anatomists, the term *basal ganglia* referred to all noncortical regions of the telencephalon (or even the forebrain), and it is convenient and useful to retain this point of view here. In mammalian development, it is thought that the basal ganglia arise from the primary ventricular ridge, which is eventually divided by a groove (the intrastriatal suclus; sis) into a *medial ventricular ridge* (VRm) that gives rise to the globus pallidus and related structures (the pallium), and a *lateral ventricular ridge* (VRl) that gives rise to the striatum and related structures

(FIG. 4). Furthermore, it should be obvious on topological grounds that the three major components of the basal ganglia must be arranged in an approximately rostral to caudal order, with the septal region (SEP) rostrally, the corpus striatum in the middle (STR, PAL), and the amygdala (AMY) caudally (also see Hines 1922; Humphrey 1972; Lammers et al. 1980).

Part B is an attempt to illustrate how structures along the midline become distorted with the evagination of the telencephalic vesicle, and why it becomes increasingly difficult to appreciate the simple topological relationships that still exist in the neural tube.

There is one serious problem with the description given above for the development of the ventricular ridges and "adjacent" rhinal or olfactory areas of the cortical mantle: it is obvious that regions thought to be derived from the ventricular ridges lie deep to the olfactory cortex (particularly the olfactory tubercle) in the adult (e.g., Atlas Level 14). There is little serious consideration of this problem in the literature, although a recent ^{3}H-thymidine autoradiographic study provides what may be an essential clue. Donkelaar and Dederen (1979) showed that the earliest neurons to differentiate in the hamster telencephalon are found in the medial septal complex, pallidum, and central nucleus of the amygdala, along with immediately adjacent parts of the olfactory cortex; aside from the olfactory regions, these are just the structures that we have included in the region of the medial ventricular ridge.

As outlined in **Part C**, it is tempting to suggest that the primary ventricular ridge (VRp) is formed by the mantle layer (dark shading in C1) that gives rise to pallial or medial ventricular ridge (VRm) structures, and that the lateral ventricular ridge (VRl) is formed by a second wave of migration (darker shading in C2) from the neuroepithelium that originally gave rise to (medial parts of) the olfactory cortex (OLF). Interestingly, this appears to be another example of the generalization that ventral parts of the neural tube differentiate earlier, and give rise to larger

neurons, than more dorsal parts. For the sake of clarity in FIG. 7, the olfactory cortex has been shifted laterally to avoid overlap with the basal ganglia.

It is now important to point out that a straightforward interpretation of the description given thus far for the development of the neural tube, and the position of adult features at earlier stages, is based on the assumption that newly generated neurons undergo a radial migration to their definitive positions. In other words, a topological map of proliferation zones in the neuroepithelium may be applied directly to the relative position of cell groups in the adult, no matter how distorted they may become. However, it has been known for many years that certain groups of neurons in the brainstem undergo rather dramatic nonradial migrations before settling in their definitive positions. The best examples of such movements involve the precerebellar nuclei, which are derived from the rhombic lip (see above), and the motor nuclei innervating striated muscle in the branchial arches (the motor nucleus of the trigeminal nerve, the facial nucleus, and the dorsal part of the nucleus ambiguus), which migrate into the hindbrain reticular formation. It is not known whether nonradial migration leads to major topological rearrangements between cell groups or areas in the forebrain. The better-known brainstem migrations have been considered in constructing FIG. 7.

The basic organization of the *ventricular system* is clearly illustrated in **Part D**: the *lateral ventricles* (VL) are associated with the telencephalic vesicles (TL), the *third ventricle* (V3) lies within the diencephalic vesicle (DI) in the midline, the *cerebral aqueduct* (AQ) lies within the midbrain vesicle (MB), the *fourth ventricle* (V4) lies within the hindbrain vesicle, and the *central canal* (C) runs down the center of the spinal cord (SP); the location of the *interventricular foramen* (of Monro; IVF) between each lateral ventricle and the third ventricle is first indicated by the torus hemisphericus (and then the di-telencephalic groove and medial striatal sulcus together; FIG. 4A, B).

Those interested in pursuing the development of the forebrain in more depth may wish to study the works of Elliot Smith (1901), Johnston (1909), Herrick (1938), Rudebeck (1945), Kahle (1951, 1956), Källén and Lindskog (1953), and Källén (1954).

Abbreviations.

ac	anterior commissure
AMY	amygdala
ANT	anterior level, hypothalamus
AQ	cerebral aqueduct
ATN	anterior nuclei, dorsal thalamus
BG	basal ganglia
C	central canal, spinal cord/medulla
cc	corpus callosum
ccg	corpus callosum, genu
ccs	corpus callosum, splenium
CNG	cingulate region
CTX	cerebral cortex
dhc	dorsal hippocampal commissure
DI	diencephalon
DOR	dorsal thalamus
dtrp	di-telencephalic roof plate
EPI	epithalamus
FRO	frontal region
GEN	geniculate nuclei, dorsal thalamus

HIP	hippocampal region
HY	hypothalamus
INF	infundibulum
INS	insular region
IVF	interventricular foramen
lam	lamina terminalis
LAT	lateral nuclei, dorsal thalamus
LS	lateral septal nucleus
LZ	lateral zone hypothalamus
MB	midbrain
ME	median eminence
MED	medial nuclei, dorsal thalamus
MEPO	median preoptic nucleus
MS	medial septal nucleus
MY	medulla
NDB	nucleus of the diagonal band
OCC	occipital region
och	optic chiasm
OV	vascular organ of the lamina terminalis
P	pons
PAL	pallidum
pc	posterior commissure
PFR	prefrontal region
PIN	pineal gland

PRO	preoptic level, hypothalamus
PRT	pretectal region
PTL	parietal region
RHI	rhinal region
SCO	subcommissural organ
SEP	septal region
SFO	subfornical organ
sme	sulcus medullaris
SOC	superior olivary complex
SP	spinal cord
ste	sulcus terminalis
STR	striatum
TE	temporal region
TEP	temporal pole
TH	thalamus
TL	telencephalon
TUB	tuberal level, hypothalamus
V3	third ventricle
V4	fourth ventricle
VENT	ventral nuclei, dorsal thalamus
vhc	ventral hippocampal commissure
VL	lateral ventricle
VNT	ventral thalamus
VRl	lateral ventricular ridge

VRm medial ventricular ridge

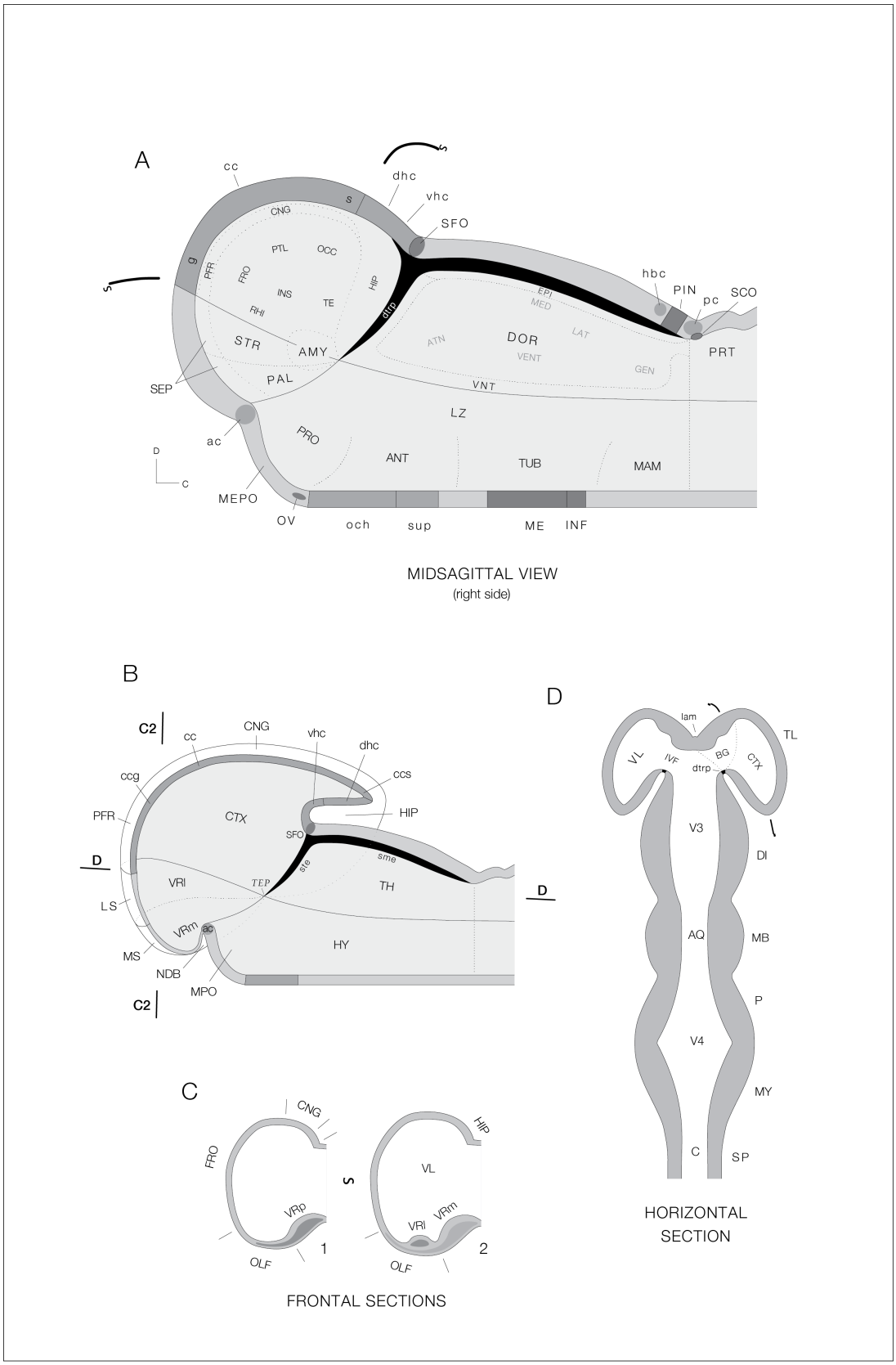

FIG. 5 *Cerebral Hemisphere Evagination*

FIGURE 6. This figure presents in a schematic way the relative positions of the major divisions of the central nervous system, and is an extension of FIGS. 4C and 5B, taking into account the massive expansion that the cerebral and cerebellar hemispheres have undergone during the later phases of development. To a first approximation, the area of each division and subdivision shown is proportional to its mass in the adult, as judged from information in the literature (Donaldson 1924) and personal dissections. The outline of the central nervous system presented here fits within the neural plate indicated in FIG. 1. To accommodate the basal ganglia, which grow caudally along with the cortical mantle (FIG. 5B), the topologically correct position of the temporal pole (TEP in FIG. 5B) has been shifted caudally (also see FIG. 7).

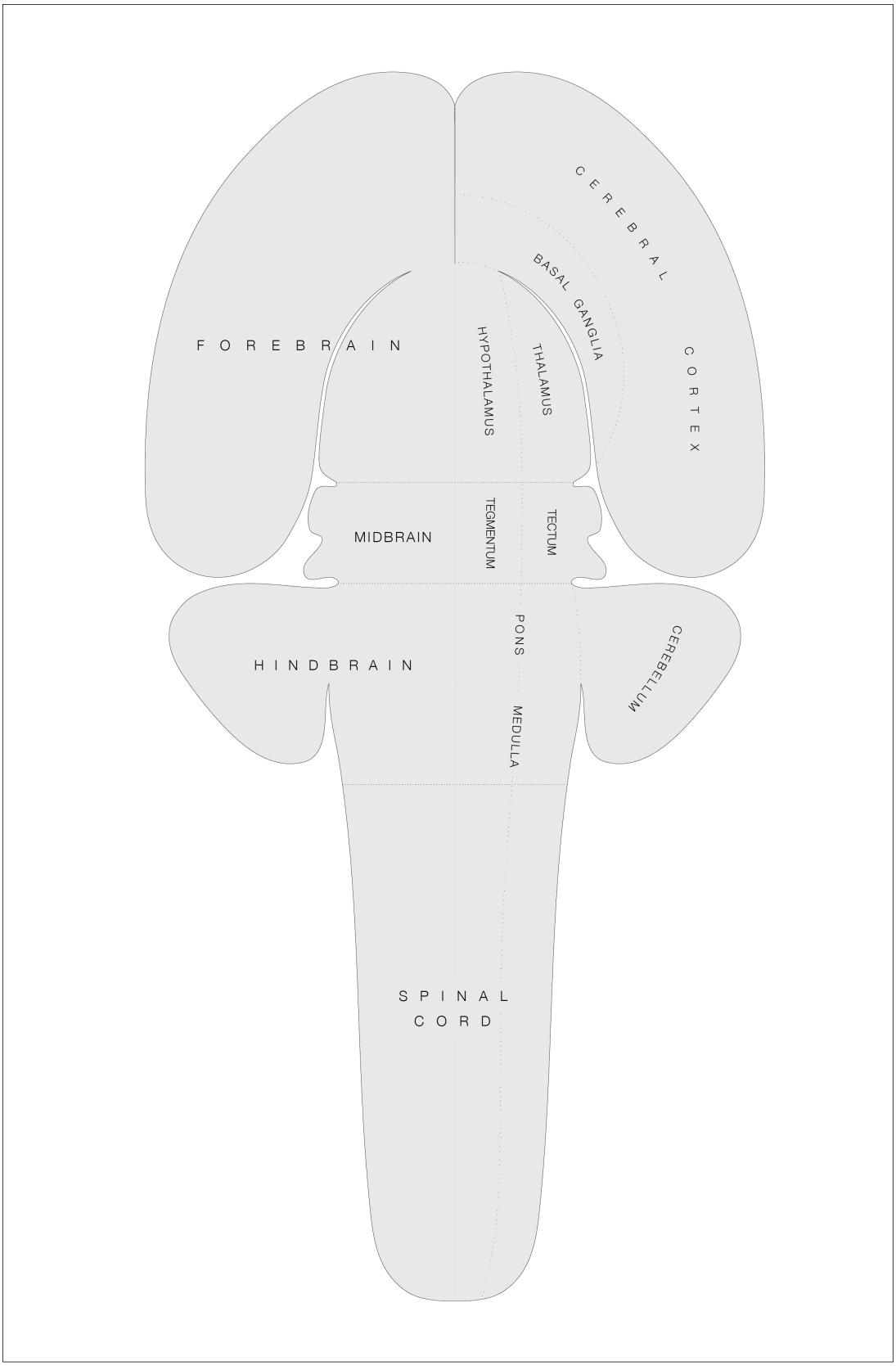

FIG. 6 *The Adult Central Nervous System*

FIGURE 7. This map illustrates the major cell groups in the adult rat central nervous system, and is based insofar as possible on the developmental information presented in the preceding figures. In essence, it is an attempt to present a topologically accurate fate map of the neuroepithelium forming the neural tube.

As discussed in FIG. 5, there are two major problems associated with such a venture. First, some groups of neurons undergo nonradial migrations that change the topological correspondence between embryonic and adult maps. The embryonic position or origin is presented here because, in general, it was found to simplify the map.

And second, it is common for several cell groups to arise sequentially from the same region of neuroepithelium, which leads to stacking in three dimensions. How can this be represented in a two-dimensional map? There are two common solutions to this problem. One involves shifting one structure relative to the other so that they no longer overlap. This is an obviously useful approach to the situation presented in FIG. 5C, where it would appear that adjacent parts of the basal ganglia and cerebral cortex may arise sequentially from the same neuroepithelial zone. The second approach involves nesting, that is, placing one structure inside another; an example of this is provided by the subthalamic nucleus.

For reasons discussed in FIG. 4, motor structures have been placed near the midline (ventrally), sensory structures laterally (dorsally), and the reticular core between the two.

Abbreviations.

AAA anterior amygdaloid area

ACA anterior cingulate area

ACB nucleus accumbens

AD anterodorsal nucleus thalamus

ADP	anterodorsal preoptic nucleus
AHA	anterior hypothalamic area
AHNa	anterior hypothalamic nucleus, anterior part
AHNc	anterior hypothalamic nucleus, central part
AHNd	anterior hypothalamic nucleus, dorsal part
AHNp	anterior hypothalamic nucleus, posterior part
AId	agranular insular area, dorsal part
AIp	agranular insular area, posterior part
AIv	agranular insular area, ventral part
AMBd	nucleus ambiguus, dorsal division
AMBv	nucleus ambiguus, ventral division
AMd	anteromedial nucleus thalamus, dorsal part
AMv	anteromedial nucleus thalamus, ventral part
AOB	accessory olfactory bulb
AON	anterior olfactory nucleus
AP	area postrema
APN	anterior pretectal nucleus
ASO	accessory supraoptic group
AT	anterior tegmental nucleus
ATN	anterior nuclei, dorsal thalamus
AUDd	dorsal auditory areas
AUDp	primary auditory area
AUDv	ventral auditory areas
AV	anteroventral nucleus thalamus

AVP	anteroventral preoptic nucleus
AVPV	anteroventral periventricular nucleus hypothalamus
B	Barrington's nucleus
BA	bed nucleus accessory olfactory tract
BLAa	basolateral nucleus amygdala, anterior part
BLAp	basolateral nucleus amygdala, posterior part
BMAa	basomedial nucleus amygdala, anterior part
BMAp	basomedial nucleus amygdala, posterior part
BST	bed nuclei stria terminalis
CEAc	central nucleus amygdala, capsular part
CEAl	central nucleus amygdala, lateral part
CEAm	central nucleus amygdala, medial part
CEC	central cervical nucleus
CL	central lateral nucleus thalamus
CLI	central linear nucleus raphé
CM	central medial nucleus thalamus
COAa	cortical nucleus amygdala, anterior part
COApl	cortical nucleus amygdala, posterior part, lateral zone
COApm	cortical nucleus amygdala, posterior part, medial zone
CSl	superior central nucleus raphé, lateral part
CSm	superior central nucleus raphé, medial part
CU	cuneate nucleus
CUN	cuneiform nucleus
DCO	dorsal cochlear nucleus

DMHa dorsomedial nucleus hypothalamus, anterior part

DMHp dorsomedial nucleus hypothalamus, posterior part

DMHv dorsomedial nucleus hypothalamus, ventral part

DMX dorsal motor nucleus vagus nerve

DT dorsal terminal nucleus accessory optic tract

DTN dorsal tegmental nucleus

ECO efferent cochlear group

ECT ectorhinal area

ENTl1-6 entorhinal area, lateral part, layers 1-6

ENTm1-6 entorhinal area, medial part, dorsal zone, layers 1-6

ENTmv entorhinal area, medial part, ventral zone

EV efferent vestibular nucleus

EW Edinger-Westphal nucleus

FF fields of Forel

FRP frontal pole

GEN geniculate nuclei, dorsal thalamus

GR gracile nucleus

GRN gigantocellular reticular nucleus

IA intercalated nuclei amygdala

IAD interanterodorsal nucleus thalamus

ICB infracerebellar nucleus

ICc inferior colliculus, central nucleus

ICd inferior colliculus, dorsal nucleus

ICe inferior colliculus, external nucleus

IF	interfascicular nucleus raphé
IGL	lateral geniculate complex, intergeniculate leaflet
ILM	intralaminar nuclei, dorsal thalamus
IMD	intermediodorsal nucleus thalamus
IO	inferior olivary complex
ISN	inferior salivatory nucleus
IV	trochlear nucleus
LA	lateral nucleus amygdala
LAT	lateral nuclei, dorsal thalamus
LAV	lateral vestibular nucleus
LC	locus coeruleus
LCN	lateral cervical nucleus
LD	lateral dorsal nucleus thalamus
LDT	laterodorsal tegmental nucleus
LGd	lateral geniculate complex, dorsal part
LGvl	lateral geniculate complex, ventral part, lateral zone
LGvm	lateral geniculate complex, ventral part, medial zone
LM	lateral mammillary nucleus
LP	lateral posterior nucleus thalamus
LRN	lateral reticular nucleus
LS	lateral septal nucleus
LT	lateral terminal nucleus accessory optic tract
MA	magnocellular preoptic nucleus
MAN	medial accessory nucleus

MARN magnocellular reticular nucleus

MDc mediodorsal nucleus thalamus, central part

MDl mediodorsal nucleus thalamus, lateral part

MDm mediodorsal nucleus thalamus, medial part

MDRNd medullary reticular nucleus, dorsal part

MDRNv medullary reticular nucleus, ventral part

MEAad medial nucleus amygdala, anterodorsal part

MEAav medial nucleus amygdala, anteroventral part

MEApd-a,b,c medial nucleus amygdala, posterodorsal part, sublayers a-c

MEApv medial nucleus amygdala, posteroventral part

MEPO median preoptic nucleus

MEV mesencephalic nucleus of the trigeminal

MGd medial geniculate complex, dorsal part

MGm medial geniculate complex, medial part

MGv medial geniculate complex, ventral part

MH medial habenula

MID midline nuclei, dorsal thalamus

MM medial mammillary nucleus

MOp primary motor area

MOs secondary motor areas

MPNc medial preoptic nucleus, central part

MPNl medial preoptic nucleus, lateral part

MPNm medial preoptic nucleus, medial part

MPO medial preoptic area

MPT	medial pretectal area
MRN	mesencephalic reticular nucleus
MS	medial septal nucleus
MT	medial terminal nucleus accessory optic tract
MV	medial vestibular nucleus
NB	nucleus brachium inferior colliculus
ND	nucleus of Darkschewitsch
NDB	nucleus of the diagonal band
NI	nucleus incertus
NIS	nucleus intercalatus
NLL	nucleus of the lateral lemniscus
NLOT	nucleus of the lateral olfactory tract
NOT	nucleus of the optic tract
NPC	nucleus of the posterior commissure
NR	nucleus of Roller
NTB	nucleus of the trapezoid body
NTS	nucleus of the solitary tract
OCP	occipital pole
OP	olivary pretectal nucleus
ORBl	orbital area, lateral part
ORBm	orbital area, medial part
ORBv	orbital area, ventral part
ORBvl	orbital area, ventrolateral part
OV	vascular organ of the lamina terminalis

PA	posterior nucleus amygdala
PAA	piriform-amygdaloid area
PAG	periaqueductal gray
PARN	parvicellular reticular nucleus
PAS	parasolitary nucleus
PAT	paratrigeminal nucleus
PB	parabrachial nucleus
PBG	parabigeminal nucleus
PCG	pontine central gray
PCN	paracentral nucleus thalamus
PD	posterodorsal preoptic nucleus
PERI	perirhinal area
PF	parafascicular nucleus
PG	pontine gray
PGRN	paragigantocellular reticular nucleus
PH	posterior hypothalamic nucleus
PMd	dorsal premammillary nucleus
PMR	paramedian reticular nucleus
PMv	ventral premammillary nucleus
PN	phrenic nucleus
PO	posterior complex thalamus
POL	posterior limiting nucleus thalamus
POR	periolivary region
PP	peripeduncular nucleus

PPN	pedunculopontine nucleus
PR	perireuniens nucleus
PRN	pontine reticular nucleus
PRP	nucleus prepositus
PRT	pretectal region
PS	parastrial nucleus
PSCH	suprachiasmatic preoptic nucleus
PSV	principal sensory nucleus of the trigeminal
PT	parataenial nucleus
PVa	anterior periventricular nucleus hypothalamus
PVHd	paraventricular nucleus hypothalamus, descending division
PVHm	paraventricular nucleus hypothalamus, magnocellular division
PVHp	paraventricular nucleus hypothalamus, parvicellular division
PVi	intermediate periventricular nucleus hypothalamus
PVp	posterior periventricular nucleus hypothalamus
PVpo	preoptic periventricular nucleus
PVT	paraventricular nucleus thalamus
RCH	retrochiasmatic area
RE	nucleus reuniens
RH	rhomboid nucleus
RL	rostral linear nucleus raphé
RR	mesencephalic reticular nucleus, retrorubral area
RSP	retrosplenial area
RT	reticular nucleus thalamus

SAG	nucleus sagulum
SBPV	subparaventricular zone hypothalamus
SC	superior colliculus
SCH	suprachiasmatic nucleus
SCO	subcommissural organ
SF	septofimbrial nucleus
SFO	subfornical organ
SG	supragenual nucleus
SGN	supragenicular nucleus
SLC	subcoeruleus nucleus
SLD	sublaterodorsal nucleus
SMT	submedial nucleus thalamus
SOCl	superior olivary complex, lateral part
SOCm	superior olivary complex, medial part
SPFm	subparafascicular nucleus thalamus, magnocellular part
SPFp	subparafascicular nucleus thalamus, parvicellular part
SPIV	spinal vestibular nucleus
SPVC	spinal nucleus of the trigeminal, caudal part
SPVI	spinal nucleus of the trigeminal, interpolar part
SPVO	spinal nucleus of the trigeminal, oral part
SSN	superior salivatory nucleus
SSp	primary somatosensory area
SSs	supplemental somatosensory area
STN	subthalamic nucleus

SUBd	subiculum, dorsal part
SUBv	subiculum, ventral part
SUMl	supramammillary nucleus, lateral part
SUMm	supramammillary nucleus, medial part
SUV	superior vestibular nucleus
TE	temporal region
TEP	temporal pole
TM	tuberomammillary nucleus
TR	postpiriform transition area
TRN	tegmental reticular nucleus, pontine gray
TRS	triangular nucleus septum
TTd	taenia tecta, dorsal part
TTv	taenia tecta, ventral part
TUA	tuberal area, hypothalamus
VAL	ventral anterior-lateral complex thalamus
VCOa	ventral cochlear nucleus, anterior part
VCOp	ventral cochlear nucleus, posterior part
VI	abducens nucleus
VISal	anterolateral visual area
VISam	anteromedial visual area
VISli	intermediolateral visual area
VISll	laterolateral visual area
VISlla	anterior laterolateral visual area
VISpl	posterolateral visual area

VISpm	posteromedial visual area
VISrl	rostrolateral visual area
VM	ventral medial nucleus thalamus
VPL	ventral posterolateral nucleus thalamus
VPLpc	ventral posterolateral nucleus thalamus, parvicellular part
VPM	ventral posteromedial nucleus thalamus
VPMpc	ventral posteromedial nucleus thalamus, parvicellular part
VTA	ventral tegmental area
VTN	ventral tegmental nucleus
x	nucleus x
XI	nucleus of the spinal accessory nerve
y	nucleus y
z	nucleus z
ZIda	zona incerta, dopaminergic group

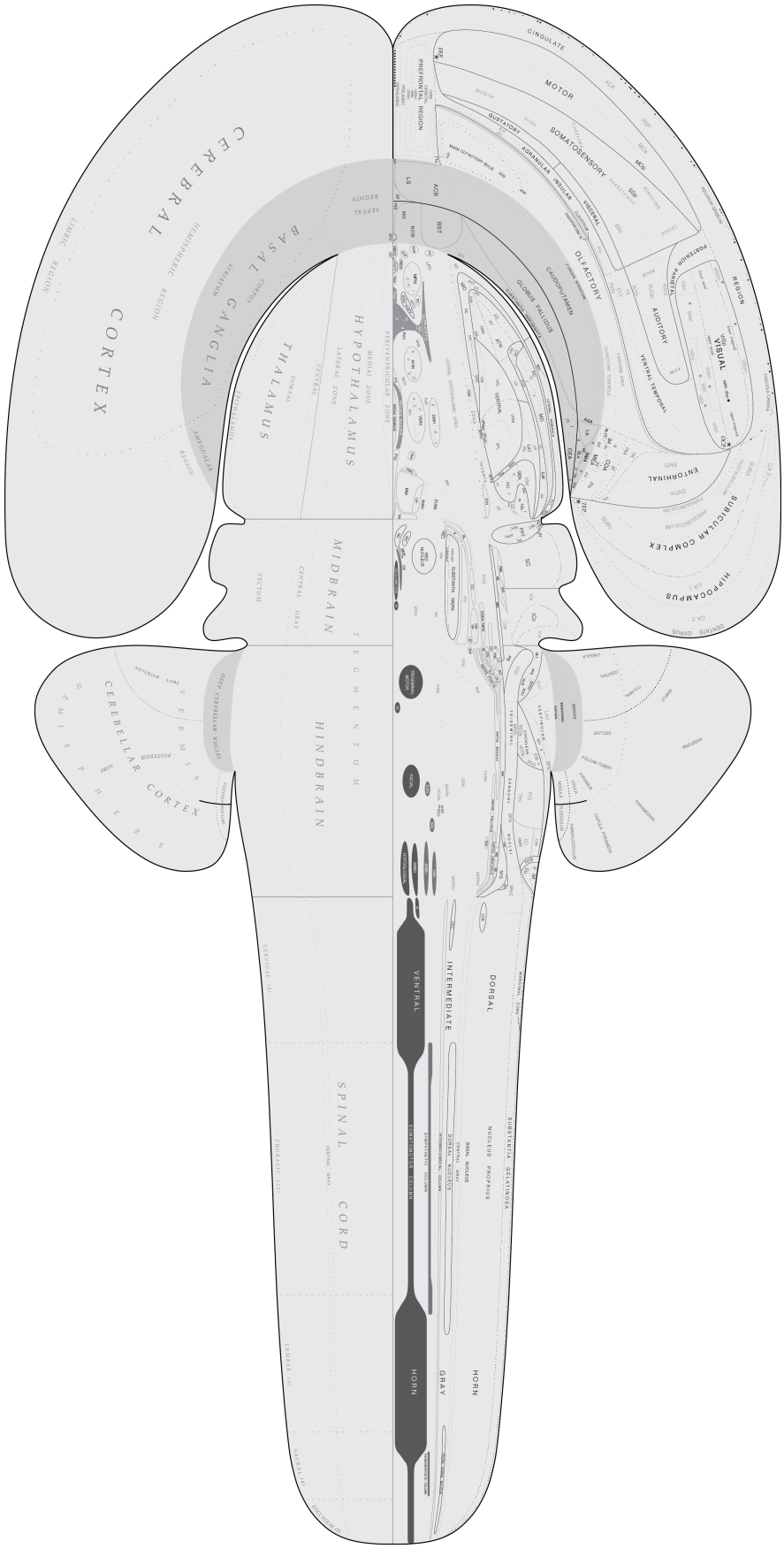
CEREBRAL
CORTEX
BASAL GANGLIA
THALAMUS
HYPOTHALAMUS
MIDBRAIN
HINDBRAIN
CEREBELLAR CORTEX
SPINAL CORD
MOTOR
SOMATOSENSORY
CINGULATE
OLFACTORY
AUDITORY
VISUAL
ENTORHINAL
SUBICULAR COMPLEX
HIPPOCAMPUS
VENTRAL
INTERMEDIATE
DORSAL
HORN
GRAY

FIGURE 8. An exploded view of the adult central nervous system, based on FIG. 6. Representations such as this may be useful in developing schematic wiring diagrams of neural circuitry. The inset (lower right) shows how pathways may be illustrated on the outline presented in Figs. 6 and 7; the general subtelencephalic projections of the motor cortex and medial prefrontal cortex are used for comparison.

Abbreviations.

BG	basal ganglia
CB	cerebellum
CTX	cerebral cortex
DI	diencephalon
FB	forebrain
HB	hindbrain
HY	hypothalamus
lfb	lateral forebrain bundle
MB	midbrain
mfb	medial forebrain bundle
MY	medulla
P	pons
SP	spinal cord
TC	tectum
TG	tegmentum
TH	thalamus
TL	telencephalon

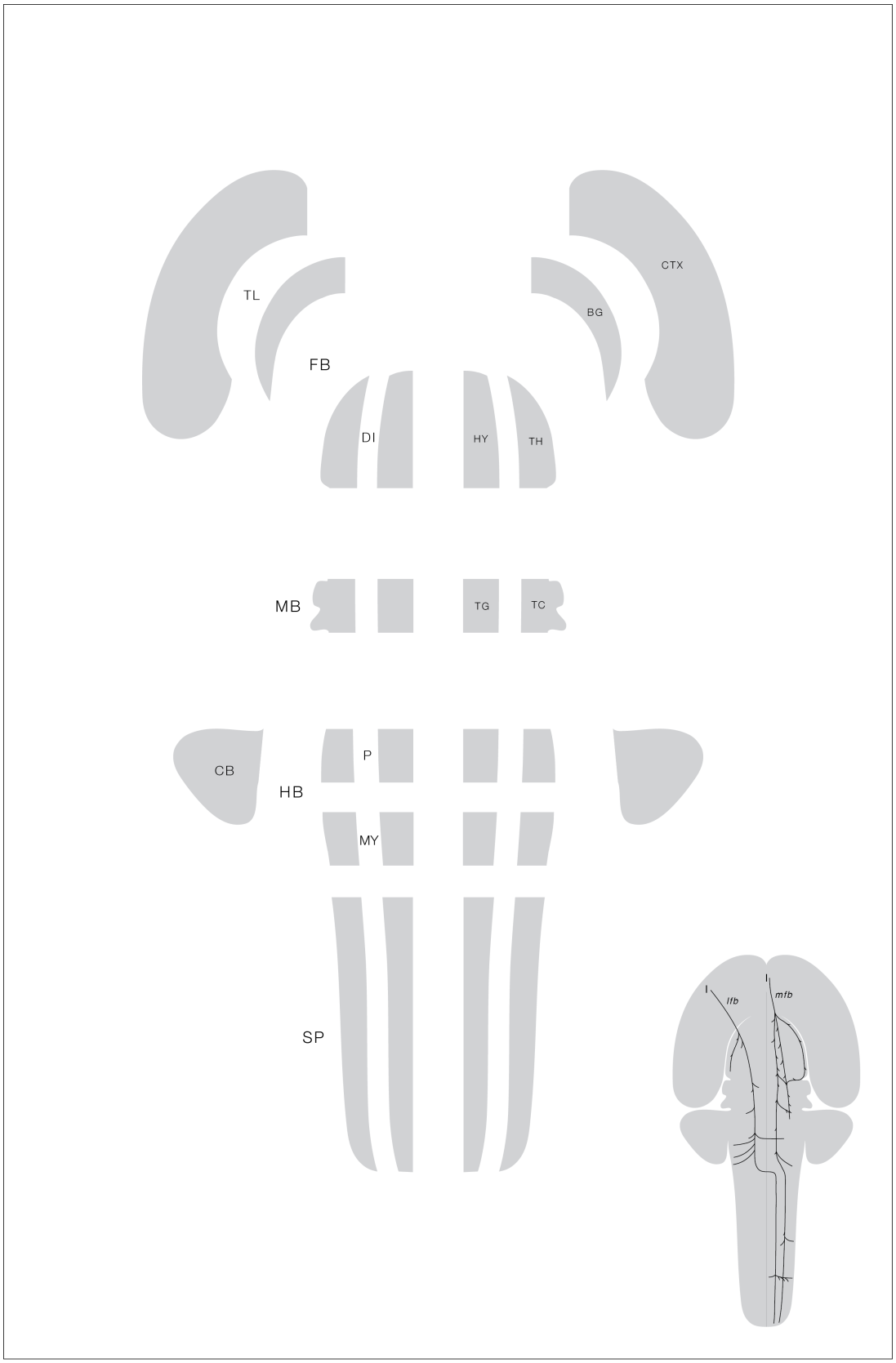

FIG. 8 *Exploded CNS*

FIGURE 9. This drawing illustrates the major features observed when viewing midline regions of the right half of a bisected adult rat brain.

Abbreviations.

AL	pituitary gland, anterior lobe
AP	area postrema
AQ	cerebral aqueduct
C	central canal, spinal cord/medulla
CB	cerebellum
CNG	cingulate region
drp	diencephalic roof plate
hbc	habenular commissure
HIP	hippocampal region
HY	hypothalamus
IL	pituitary gland, intermediate lobe
IVF	interventricular foramen
lam	lamina terminalis
LS	lateral septal nucleus
ME	median eminence
MOB	main olfactory bulb
MS	medial septal nucleus
MY	medulla
NDB	nucleus of the diagonal band
P	pons

PFR	prefrontal region
PIN	pineal gland
PL	prelimbic area
PMv	ventral premammillary nucleus
SFO	subfornical organ
SP	spinal cord
TC	tectum
TG	tegmentum
TH	thalamus
V3	third ventricle
V4	fourth ventricle

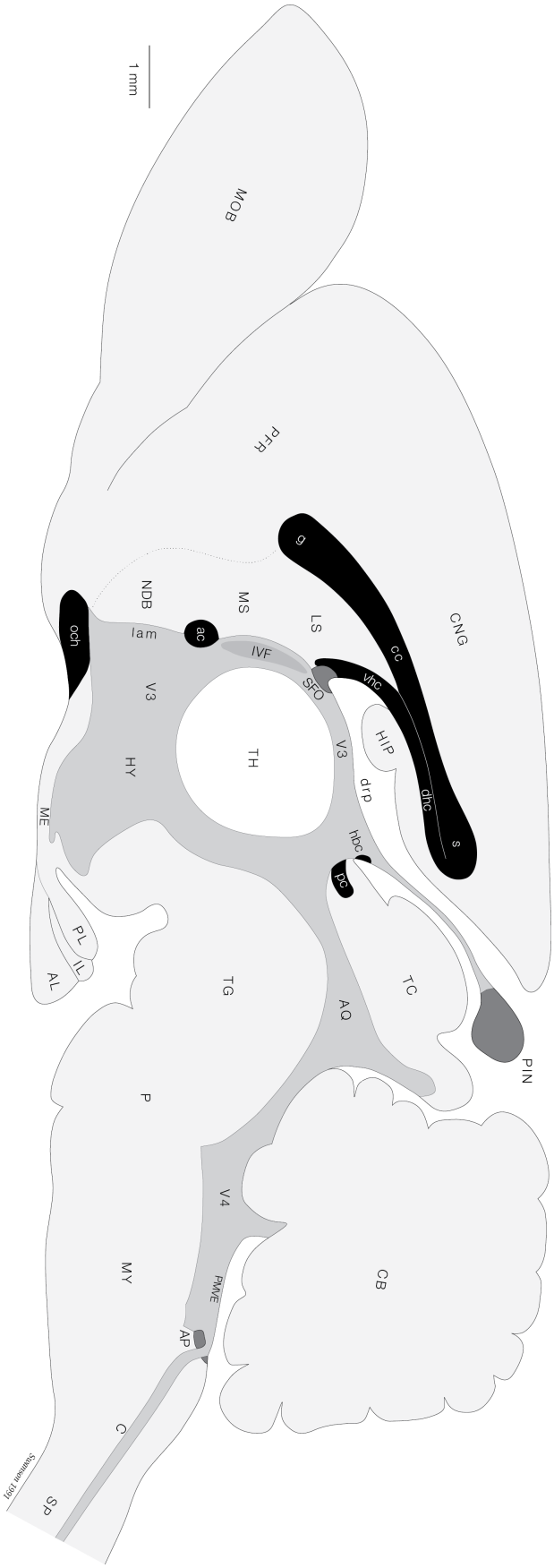

FIG. 9 *The Rat Brain (Midsagittal View)*

FIGURE 10. An overview of the adult rat nervous system, showing the major outlines of its central and peripheral components. Information on the general disposition of the nerves in the rat may be found in Greene (1968) and in Hebel and Stromberg (1986).

Abbreviations.

1 hypoglossal nerve

2 proximal and distal vagal ganglia (rostrally), superior cervical ganglion (caudally)

3 cervical plexus

4 brachial plexus

5 sympathetic trunk

6 phrenic nerve

7 splanchnic nerves

8 first lumbar spinal ganglion

9 coeliac ganglion

10 lumbosacral plexus

11 first sacral spinal ganglion

12 pudendal plexus

13 third coccygeal spinal ganglion

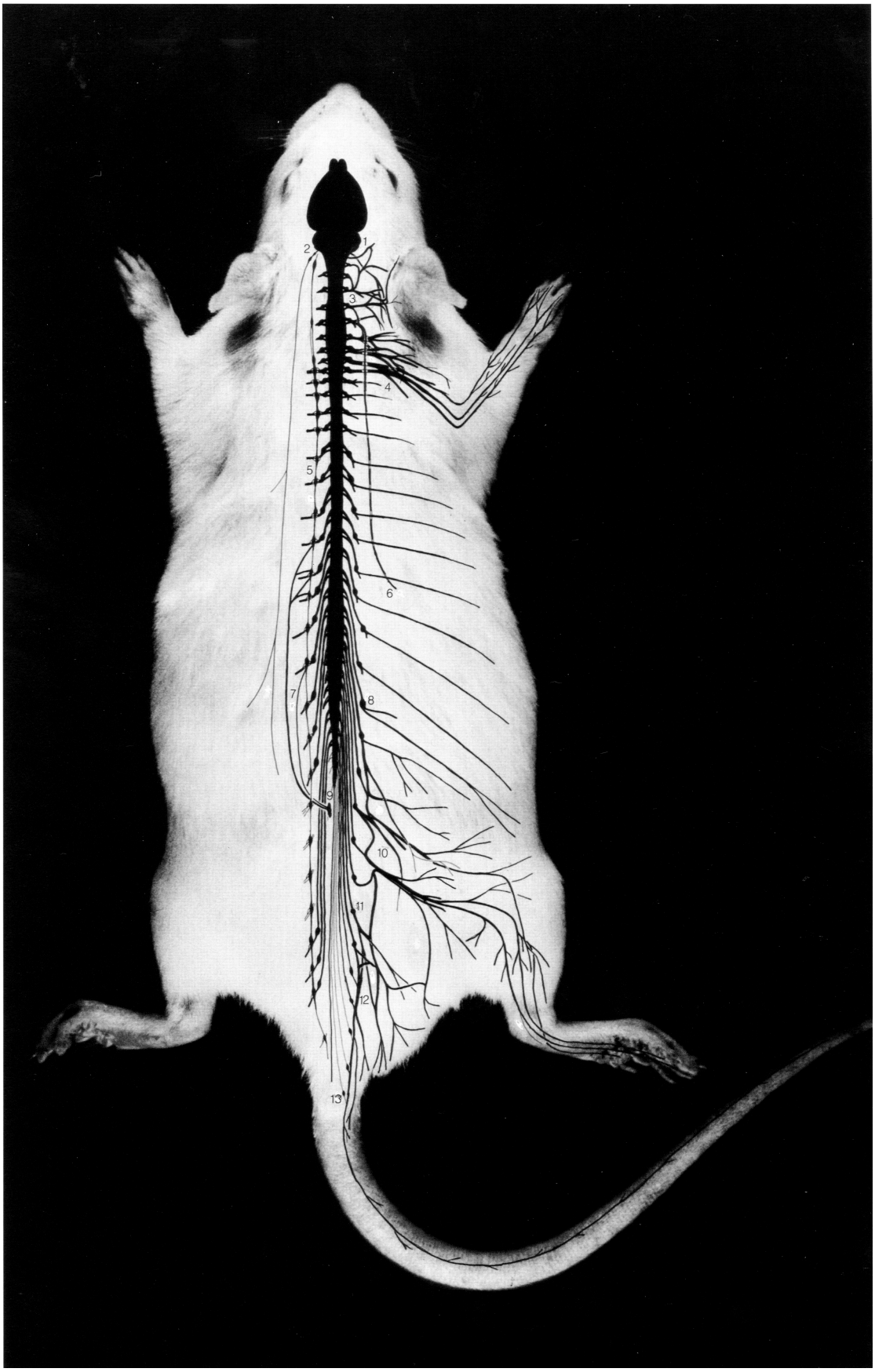
1
2
3
4
5
6
7
8
9
10
11
12
13